

CASE STUDY: Long Tunnel PFO Closure with *ultrasept*

ultrasept

Patent Foramen Ovale Closure Device

Our Thanks to:

Professor Victor Legrand
Department of Interventional Cardiology
Centre Hospitalier Universitaire de Liège, Belgium

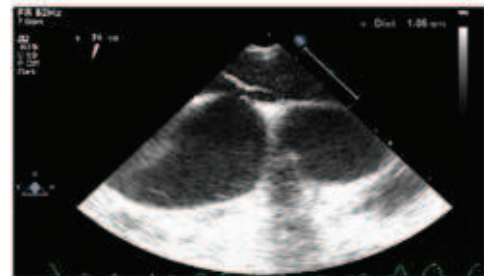A 41 year-old male patient with a recent cerebellar event was referred to our Cardiology Department for the closure of a patent foramen ovale (PFO).

Initial TEE investigations confirmed a PFO with a large atrial septal aneurysm (ASA). Bubble contrast study showed a right-to-left shunt during Valsalva along with a long PFO tunnel. TEE excluded any valvular or cardiac disorders, and no other risk factors were present.

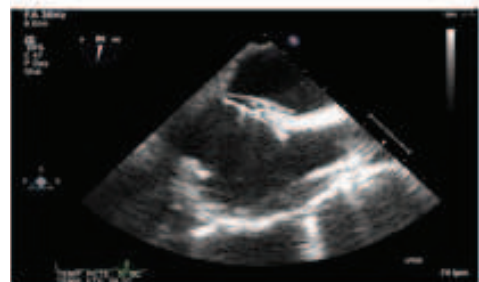
The patient was selected for percutaneous PFO closure, and general anesthesia was administered together with TEE. The PFO was crossed with an exchange wire and replaced by an 11 French Mullins sheath, which was then positioned in the left pulmonary vein. Through this, a 30mm *ultrasept* device (Cardia, Eagan, MN, USA) was deployed in proper position under TEE guidance.

The device was implanted with no residual shunt or other complications. The total duration of the procedure was 45 minutes with fluoroscopy time of less than six minutes.

An echocardiogram and chest x-ray showed the device in correct position at the 24 hour follow up, and the patient was discharged.



Long Tunnel PFO



Complete Closure of PFO with Long Tunnel

Background.

The circular *ultrasept* (Cardia, Eagan, MN, USA) is a low profile, fully retrievable and repositionable device. It employs hands-free loading of its stranded Nitinol frame and dual articulating polyvinyl alcohol sails. It is used for transcatheter closure of the patent foramen ovale (PFO).