

Our thanks to:

Dr. Pierre Materne, Dr. Etienne Hoffer
Hopital La Citadelle
Liege, Belgium

Case Study – Platypnea-Orthodeoxia and patent foramen ovale (PFO): Successful treatment of symptoms by percutaneous PFO closure

Introduction

Dyspnea and arterial desaturation on upright position in elderly subjects is described as platypnea-orthodeoxia syndrome (POS). POS is characterized by two key factors: increased dyspnea in the upright position, relieved by assuming the recumbent position (platypnea) and the development or accentuation of hypoxemia in the upright position (orthodeoxia). While the etiology of POS is not well understood, the syndrome is seen in association with several pulmonary disorders such as post-pneumonectomy or lobectomy, as well as obstructive lung disease. In some patients, POS is due to a right to left shunt across the atrial septal defect (ASD)/ patent foramen ovale (PFO). Evidence shows that closure of a PFO is clearly indicated to relieve the symptoms of patients with POS.

Case Report

A 66 year old man was admitted to the hospital with a history of hypertension and hypothyroidism. Transesophageal echocardiogram (TEE) detected a PFO with an atrial septal aneurysm and a right to left shunt (agitated physiological saline). Transcatheter closure of the PFO was indicated due to the incapacitating symptoms caused by orthodeoxia.

Interventional closure of PFO was attempted using a 25 mm Intrasept PFO device (Cardia Inc. Eagan, MN). The Intrasept PFO device is a self-expandable, double umbrella device, containing six stranded Nitinol arms covered with poly-vinyl alcohol. A 12F sheath was used to deliver the 25mm INTRASEPT occluder. After device implantation, the atrial septal aneurysm was stabilized and partially located in-between the two umbrellas of the device, as well as completely closed.

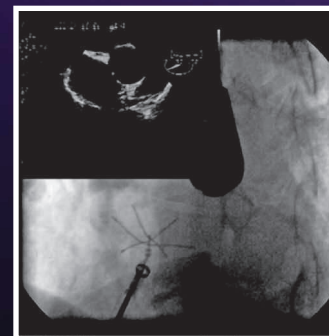
Conclusion:

Closure of a PFO has been clearly proven to relieve the symptoms of patients with POS. The patients usually have significant comorbidities that make them high-risk surgical candidates. Transcatheter PFO closure serves as a safe, effective and less invasive alternative to surgical closure.

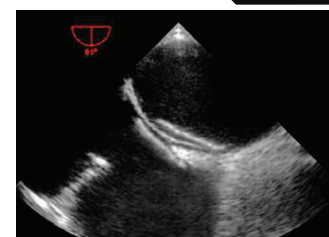
This procedure can be done with either transthoracic, transoesophageal or intracardiac echocardiographic guidance and requires on average, only a one-day stay in the hospital. For this reason, it is believed that transcatheter closure will become the treatment of choice for closure of PFO's associated with POS.

References

1. Rao PS, Palacios IF, Bach RG, Bitar SR, Sideris EB. Platypnea-orthodeoxia: Management by Transcatheter Buttoned Device Implantation. Catheter Cardiovascular Interv. 2002 Apr; 55 (4): 529-30
2. Dogu E, Stohr A, Zick-Bogemann R, Hegeler-Molkewehrum C, Hartmann H, Engel HJ. Platypnea-orthodeoxia of a 69-year old woman with a patent foramen ovale. Zeitschrift für Kardiologie 2004 May;93(5):403-6
3. José R Ortega Trujillo, Javier Suárez de Lezo Herreros de Tejada, Antonio García Quintana, Francisco Melián Nuez, Raquel Rodríguez Delgado y Alfonso Medina Fernández-Aceytuno. Transcatheter Closure of Patent Foramen Ovale in Patients With Platypnea-Orthodeoxia. Rev. Esp. Cardiol. 2006;59:78-81



Intrasept Right-Side Deployment



Intrasept Post Release