

## Physicians Case Studies

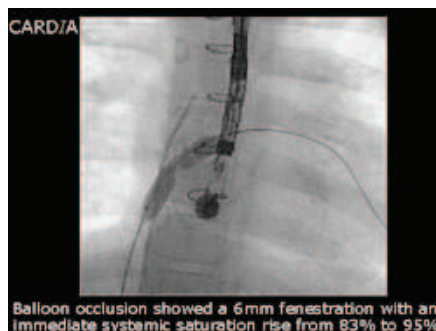
### Fontan Case Study

*Thanks To:*

The Birmingham Children's Hospital  
 Department of Pediatric Cardiology  
 Birmingham, United Kingdom  
 Dr. JV De Giovanni

An 8-year old male with a fenestrated Fontan was admitted for catheterization and possible closure of the fenestration at Birmingham Children's Hospital, United Kingdom.

Balloon occlusion of the fenestration which was responsible for the right to left shunt showed an immediate systemic saturation rise from 83% to 95%. Examination by echo and flouro confirmed an evenly margined 6mm surgical fenestration, ideal for closure.



A 15mm CARDIA (FDD-0115) Fenestrated Fontan Device was chosen with sufficient overlap, which allowed a low unobstructive baffle profile. Delivery and release of the device were uneventful. Complete closure by TEE and contrast were confirmed and the patient returned to the Ward.

Resting saturations the next day had increased to 98% and the patient was released from Birmingham Children's Hospital.

